Rat model of cavernous nerve crush injury

Model advantages:
This rat model of cavernous nerve crush injury mimics neural damages associated with radical prostatectomy in human.

Pathophysiological features:
Identically to human, the rat model of cavernous nerve crush injury displays ED (figure 1).

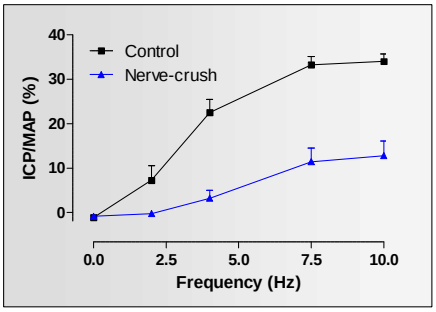

Figure 1: Effects of bilateral cavernous nerve crush injury (4 weeks post-surgery) on intracavernosal pressure (ICP) after ES CN in anesthetized rats (from Bessede T et al., 2008).

Moreover, several pathophysiological mechanisms which are linked to radical prostatectomy-associated ED in human are present in rats with cavernous nerve crush injury:

- Penile nNOS immunoreactive fibers content decrease. (The brief activation of nNOS is involved in the initiation of the erectile process causing the increase in intracavernosal pressure)
- Cavernosal tissue remodeling and fibrosis

Summarized methodology:
Briefly, bilateral cavernous nerve crush is performed in rats under anaesthesia usually 3-4 weeks before experimentation (figure 2).

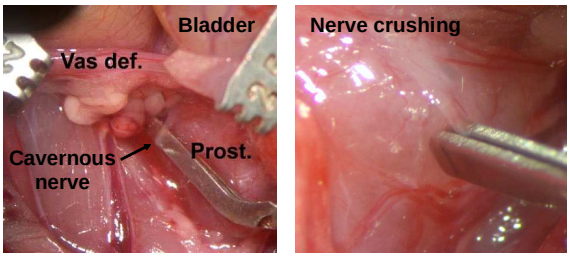

Figure 2: Per-operative view of cavernous nerve crush procedure in rats

Related Pelvipharm bibliography:

Oudot, A. et al. Eur Urol (2011) : 60(5):1020-1026
Bessede, T. et al. J Sex Med: 5 (suppl 2) (ESSM 2008)
Bessede, T. et al. Eur Urol Suppl: 7(3):161 (EAU 2008)

Links to applicable experimental skills:

- **Administration routes / regimen**
- **Plasma / urine / tissue collection**
- **In vivo experiments – conscious animals**
  * Telemetry
  * Urine collection - Metabolic cages
  * Behavioural science
- **In vivo experiments – anesthetized animals**
  * Erection elicited by pharmacological or electrical neural stimulation
- **Behavioral science**
- **Organ bath studies (EFS / Pharmacological studies)**
  * Animal tissues
- **Biochemistry (Plasma / Urine / Tissue)**
  * Spectrophotometric assays
  * Protein expression and activity
- **Histology**
  * Histomorphology
  * Histomorphometry
  * Oxydative fuorescence
- **Immunohistology / Confocal microscopy**
  * Protein expression – immunohistochemistry / immunofluorescence
  * Confocal microscopy